

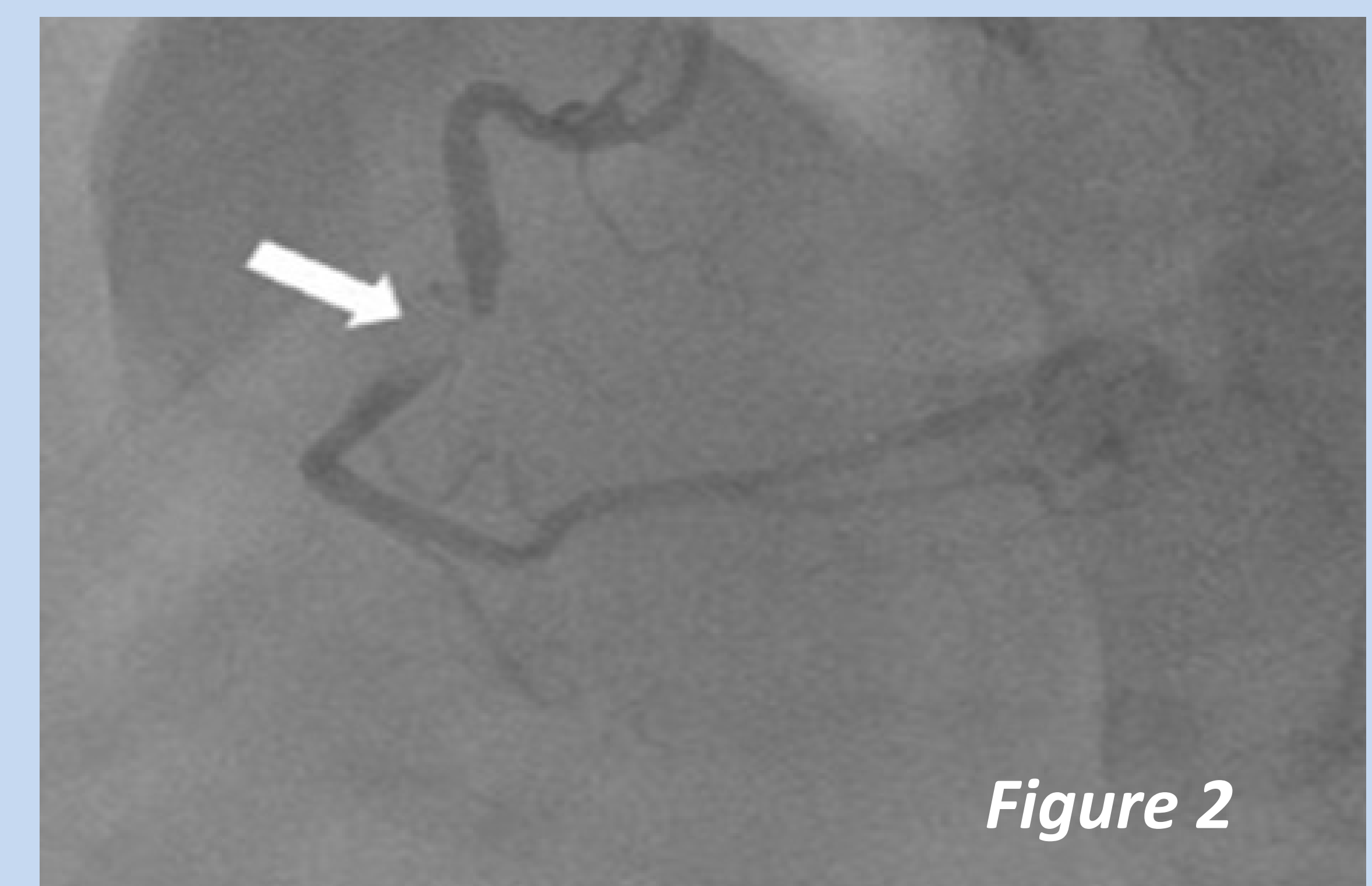
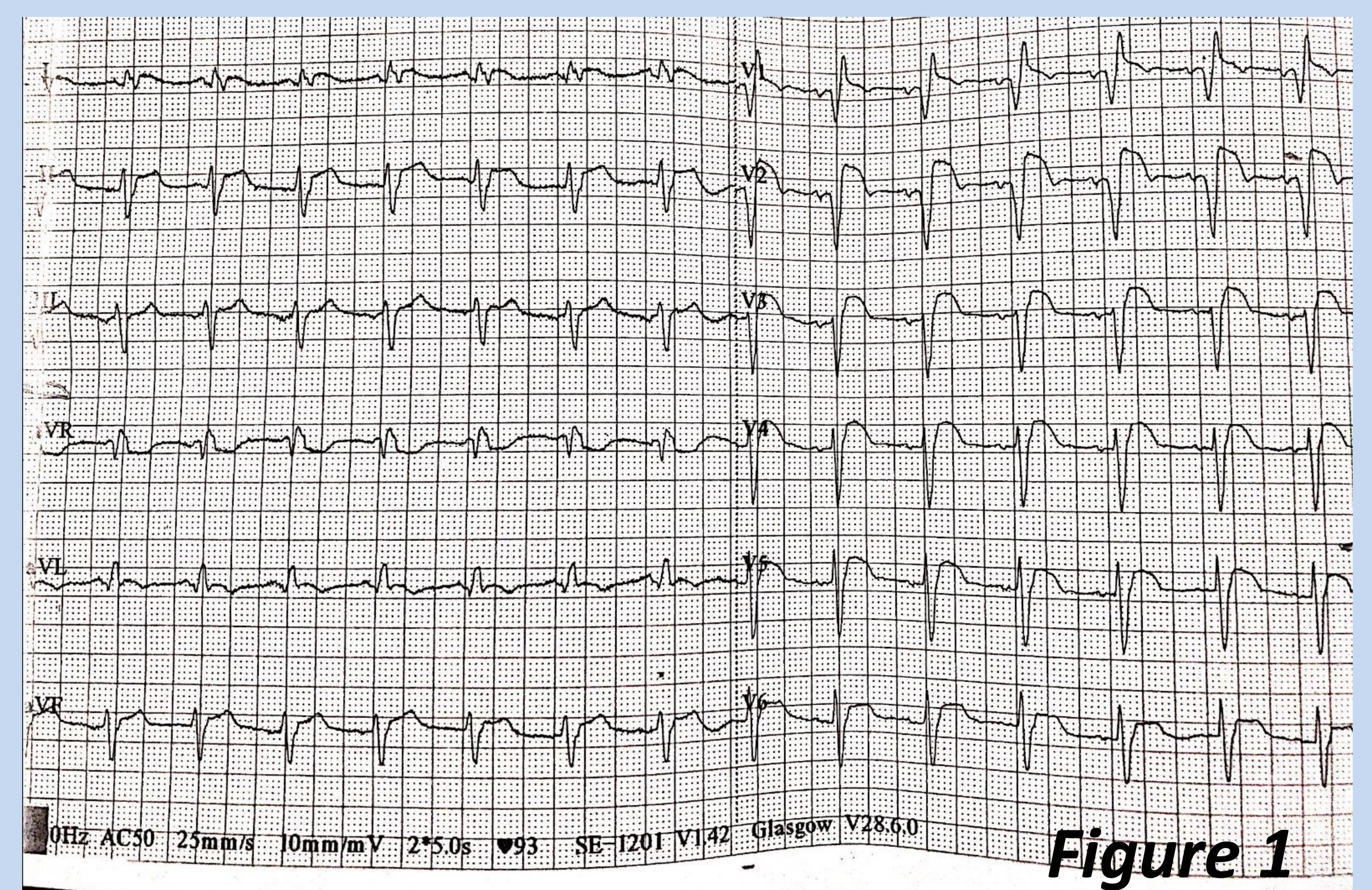
Background

Acute coronary syndrome (ACS) can present with atypical chest pain or symptoms not attributed to heart disease, such as epigastric pain, nausea, vomiting or hiccup¹. A hiccup is involuntary, paroxysmal inspiratory movement of the chest wall associated with diaphragm and accessory respiratory muscle contractions, with the synchronized closure of glottis². The center of hiccups is localized in C3–C5 segments of the spinal cord. There are various causes of protracted hiccups, including metabolic abnormalities, psychogenic disorders, malignancy, central nervous system pathology, medications, pulmonary disorders, or gastrointestinal etiologies^{1,2}.

Case presentation

We present the case a 65-years-old man, with diabetes mellitus and hypertension, who presented to the Emergency Department for a intractable hiccup started two day ago, nausea and vomiting. A routine electrocardiogram was performed and showed an anterior myocardial infarction with ST elevation (STEMI) (fig.1). Troponin I peaked at 9,78 ng/mL.

An emergency coronary angiography showed obstruction on the proximal left anterior descending coronary artery and a stent was placed (fig.2).



Discussion

Persistent hiccups as the sole presenting symptom of myocardial infarction (MI) has previously been rarely reported¹. The hiccup mechanism involves a neural reflex arc, but the exact pathway of hiccups is unknown. Several studies shown that hiccups occur more frequently in patient with inferior MI and right ventricle infarction, which can be explained by anastomoses between the frenal nerve and most of the fibers reaching the right pericardium².

Conclusion

In conclusion, although extremely common and usually benign, hiccup can occasionally be a symptom of serious underlying pathology such as STEMI. We present this case as a red flag to emergency physicians for the potential of hiccup to serve as the chief presenting symptom of STEMI.

References:

- Joshua D, Michelle D Hiccups as the only symptom of non–ST-segment elevation myocardial infarction *American Journal of Emergency Medicine* (2012) 30, 266.e1–266.e2
- Waldemar K, Slawomir S, Hiccups as a myocardial ischemia symptom *Polskie archiwum medycyny Wewnetrznej* 2008; 118 (3)