

Background:

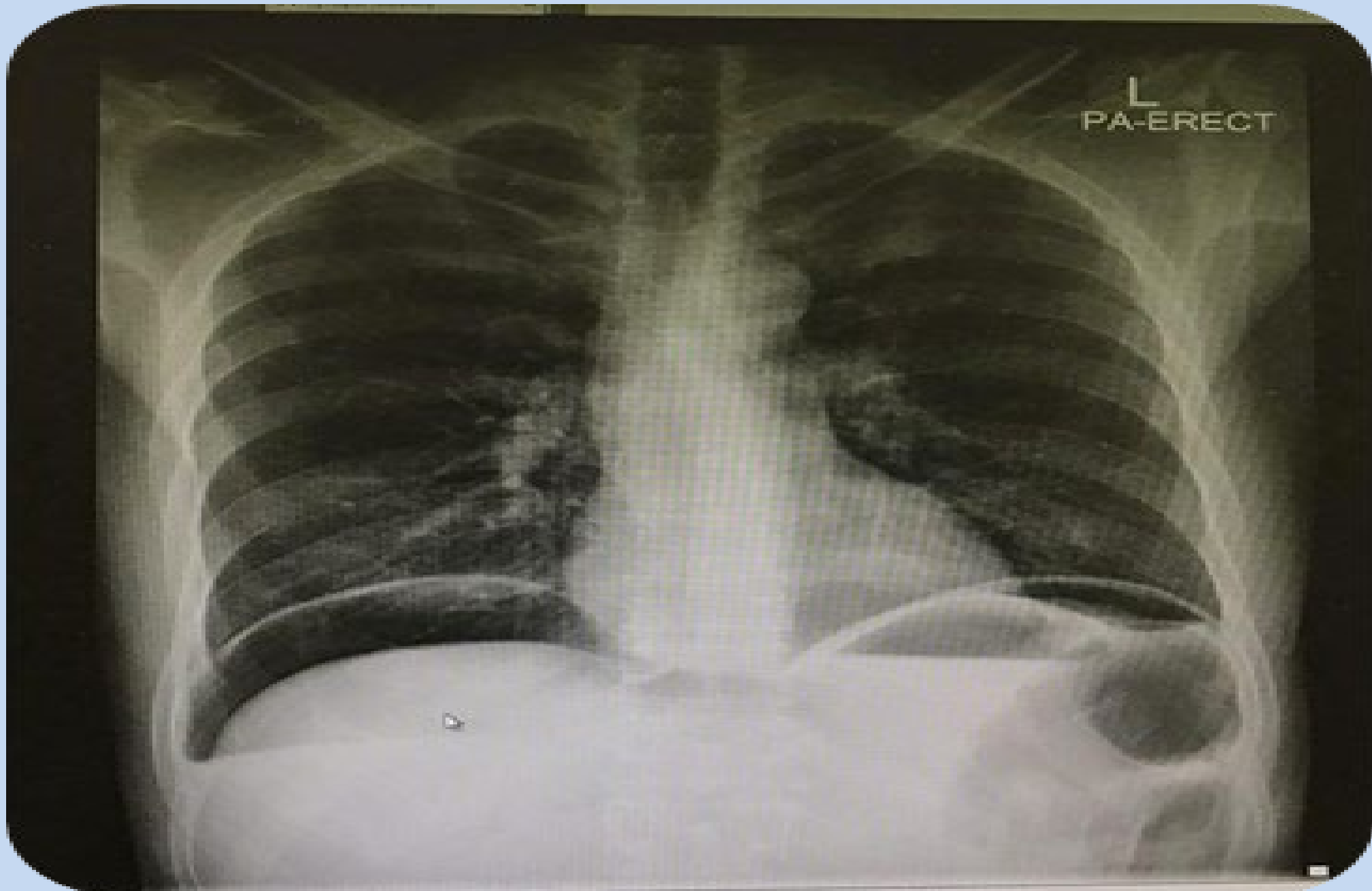
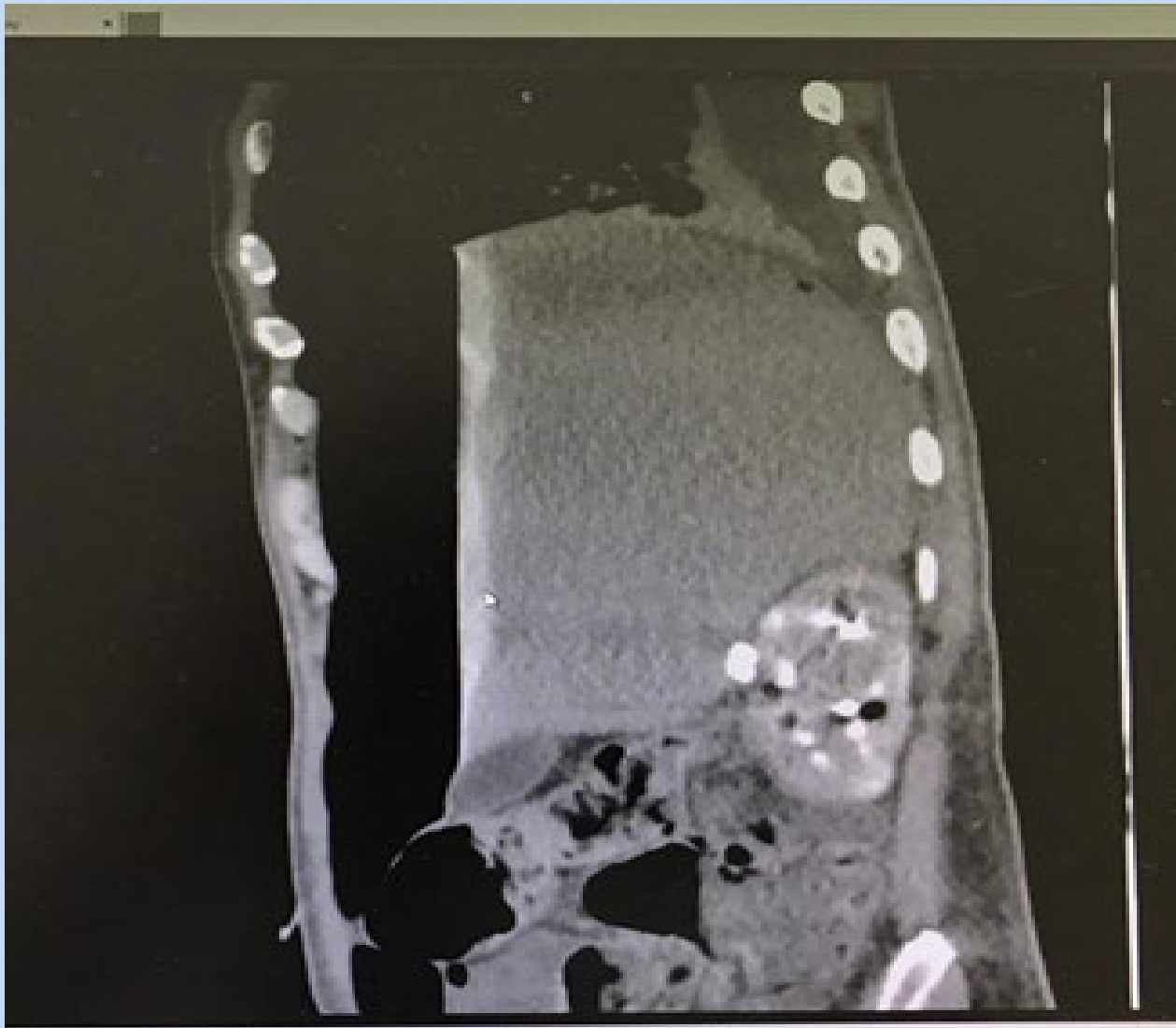
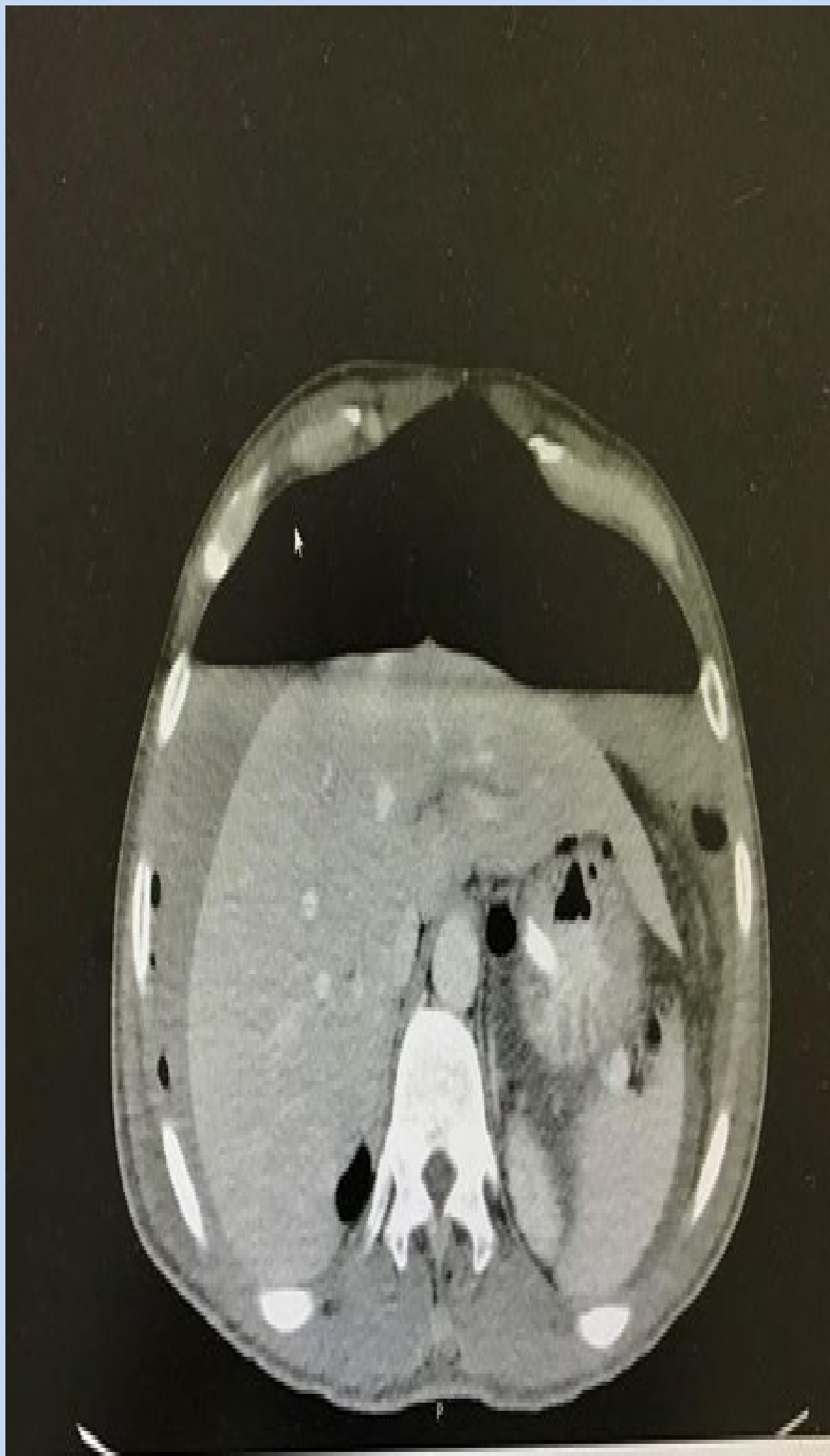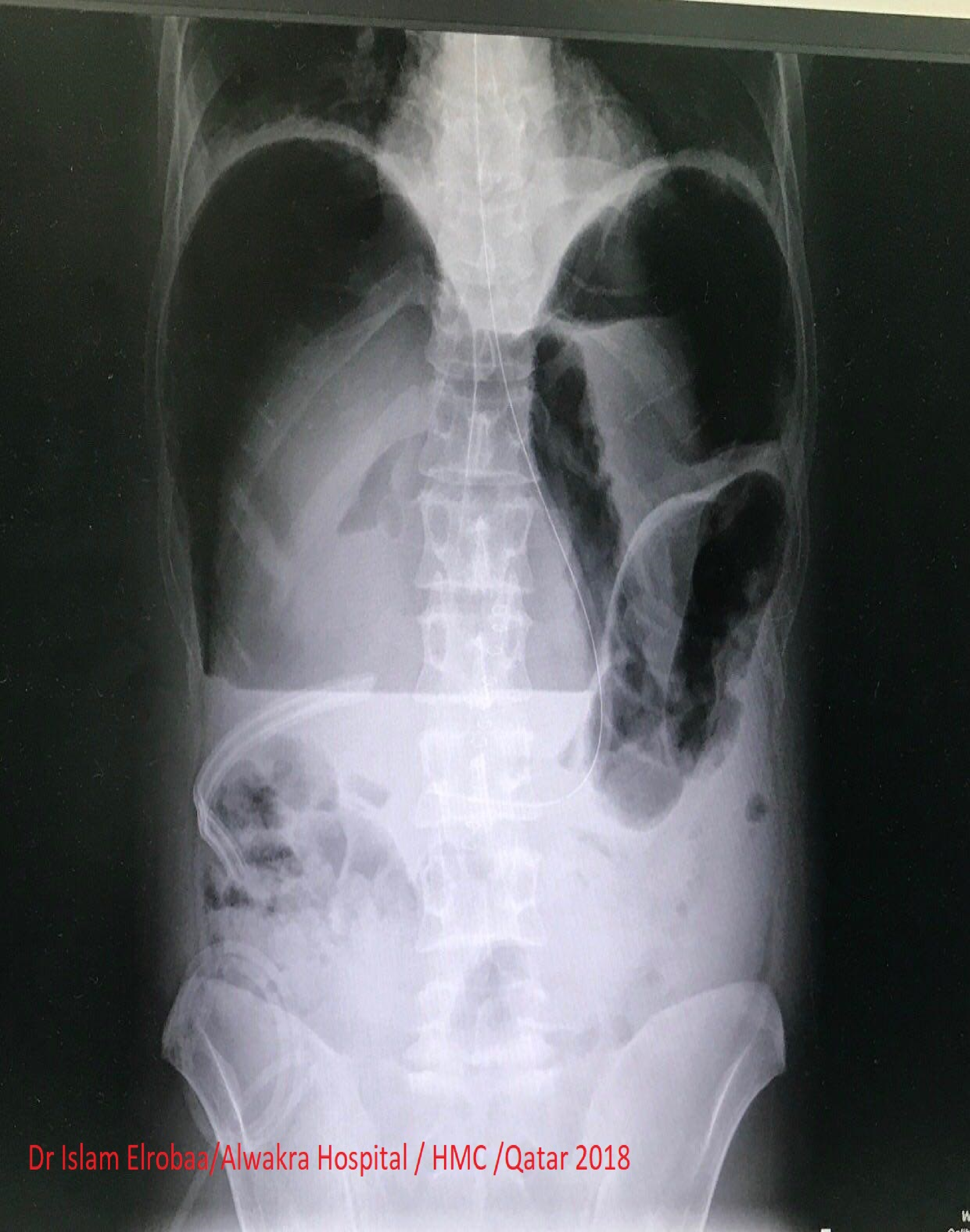
A hydropneumoperitoneum refers to free air and fluid in the peritoneal cavity. Whereas pneumoperitoneum refers to air in peritoneal cavity. The patient who has this sign may need urgent surgical intervention and if miss it the patient may die .Usually we can see this sign in chest X ray as air under diaphragm and it’s the famous sign for pneumoperitonum . The air fluid line in chest – abdomen x ray is refer to hydropneumoperitonium which is less common than pneumoperitoneum in perforated duodenal ulcer . In this case we reported huge hydropneumoperitoneum as unusual complication of duodenal ulcer with interested Images .

Patients & Methods :

Descriptive study – case report . We describe a case of acute abdominal pain that presented in emergency department and diagnosed as duodenal ulcer and repaired by surgeon then got severe abdominal pain and we reported unusual huge hydro pneumoperitoneum with interested images

Result : We have reported of significant huge hydropneumoperitoneum which is an unusual presentation in perforated duodenal ulcer . Omental patch repair does not correct the underlying process that causes perforation, and ulcers may recur .

Conclusion : Emergency physician and surgeon should be aware of unusual presentation of duodenal ulcer and other diseases. Omental patch operation could be induce huge hydropneumoperitoneum if it fails and the patient had a presentation of hydropneumoperitoneum .



References:

- <https://medical-dictionary.thefreedictionary.com/hydropneumoperitoneum>
- <http://www.wikiradiography.net/page/Pneumoperitoneum>
- Miller RE. Perforatedviscusin infants:a new roentgensign. Radiology 1960;74 :65-67
- Lau WY, Leow CK. History of perforated duodenal and gastric ulcers. World J Surg. 1997 Oct; 21(8):890-6. [Medline].
- Sarath Chandra S, Kumar SS. Definitive or conservative surgery for perforated gastric ulcer?--An unresolved problem. Int J Surg. 2009 Apr; 7 (2):136-9. [Medline].
- Stapakis JC, Thickman D. Diagnosis of pneumoperitoneum: abdominal CT vs. upright chest film. J Comput Assist Tomogr 1992;16:713-6.
- Stapfer M, Selby RR, Stain SC, et al. Management of duodenal perforation after endoscopic retrograde cholangiopancreatography and sphincterotomy. Ann Surg. 2000 Aug; 232(2):191-8. [Medline].
- NMA Williams, DFL Watkin . Spontaneous pneumoperitoneum and other nonsurgical causes of intraperitoneal free gas . Postgrad MedJ3 1997; 73: 531 – 537
- Smith D, Roeser M, Naranjo J, Carr JA. The natural history of perforated foregut ulcers after repair by omental patching or primary closure. Eur J Trauma Emerg Surg. 2017 Jul 29. [Medline].